



RESENTING CLINICAL SIGNS

History: Recheck HCM. Asymptomatic.

DATE

4/6/23

ECHOCARDIOGRAPHIC FINDINGS

2D, M-mode, and Doppler study. This exam is compared to the one performed 5/12/22.

PERFORMED BY:

Kelly Vazquez

INTERPRETED BY

Keith Blass, DVM,
MS, DACVIM
(Cardiology)

Left atrial size is normal. The mitral valve appears normal, though mild mitral regurgitation is present. There is mild hypertrophy of the interventricular septum. Left ventricular posterior wall thickness is normal. Left ventricular internal dimensions are normal. Left ventricular systolic function is hyperdynamic. The aorta and aortic valve are normal. Right atrial and right ventricular dimensions are normal. The tricuspid valve is normal. The pulmonary artery and pulmonic valve are normal. No pericardial effusion or cardiac masses are seen.

PATIENT

Dallas Morales

LA/Ao - 1.45 (prev. 1.44)
IVSd - 6.5 mm (prev. 6.5 mm)
LVPWd - 4.9 mm (prev. 4.8 mm)
LVIDd - 16.3 mm (prev. 16.0 mm)
LVIDs - 6.2 mm (prev. 5.5 mm)
FS - 62% (prev. 65.6%)
LVOT - 1.15 m/s (prev. 1.79 m/s)
RVOT - 1.01 m/s (prev. 1.29 m/s)

ASSESSMENT/RECOMMENDATIONS

SPECIES

Feline

This examination demonstrates no progression of Dallas's cardiac disease over the past 11 months. As such, his risk for the development of congestive heart failure and/or thromboembolic disease still appear to be low, though careful monitoring for clinical signs associated with these conditions is still recommended.

BREED

DSH

Dallas's cardiovascular risk for general anesthesia is mildly increased based on this exam, therefore, some precautions should be taken in order to minimize this risk. I recommend avoiding the use of alpha-2 agonists, ketamine, and telazol in the anesthetic protocol, as well as reducing the IV fluid rate by 25%. If possible, monitoring of heart rhythm, blood pressure, and pulse oximetry are recommended during the procedure.

SEX

MN

No therapy is recommended at this stage of disease.

AGE

A recheck echocardiogram is recommended in ~9 months. Thoracic radiographs are recommended if Dallas experiences respiratory clinical signs.

6 y

WEIGHT

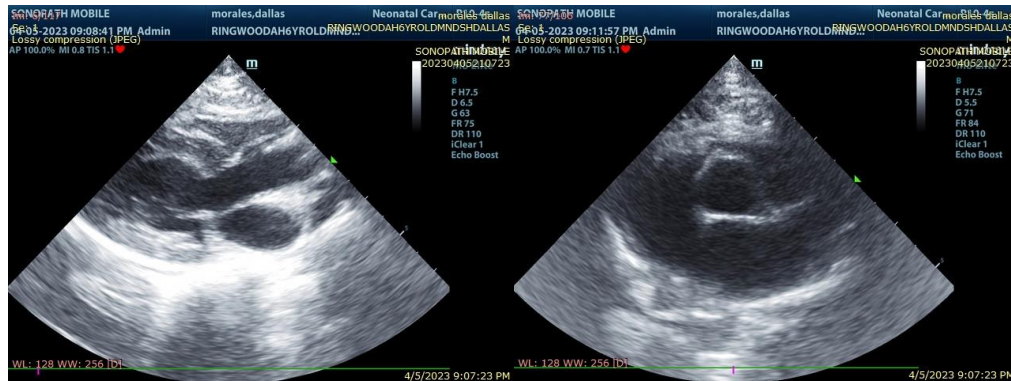
13.4 lb

HOSPITAL NAME

Ringwood AH

REFERRING VET

Dr. Walker





DATE

4/6/23

The information and recommendations provided are based on the images presented by the referring veterinarian. No evaluation can be communicated regarding pathology that was not visible in the image/video clips provided.

PERFORMED BY:

Kelly Vazquez

Thank you for this referral. If the clinical or image interpretation does not parallel your findings or if I can be of any further assistance please contact me.

INTERPRETED BY

Keith Blass, DVM,
MS, DACVIM
(Cardiology)

Keith Blass, DVM, MS, DACVIM (Cardiology)
KeithBlass@gmail.com
631-804-5754

PATIENT

Dallas Morales

SPECIES

Feline

BREED

DSH

SEX

MN

AGE

6 y

WEIGHT

13.4 lb

HOSPITAL NAME

Ringwood AH

REFERRING VET

Dr. Walker